

Ovarian Fibroma as a Possible Cause of Fever of Unknown Origin

İkbal KAYGUSUZ¹, Ayla ESER¹, İlknur İNEGÖL GÜMÜŞ¹, İsmail KIRBAŞ², Kayıhan AKIN², Hacer HALTAS³
Hasan KAFALI¹

Ankara, Turkey

ABSTRACT

Fibromas are the most common benign solid tumors of the ovary. Clinically, they are asymptomatic and preoperative diagnosis is often difficult. In this paper we report a case of fibroma as a cause of fever of unknown origin (FUO).

A 26-year-old woman referred to our hospital with a one-month history of intermittent fever. Ultrasonography as well as pelvic computed tomography scans showed a hypoechoic appearance in the right adnexal region which was diagnosed as pyosalpinx, in the light of clinical setting. Pus drainage was then planned but 3cc of serous material was drained from the adnexal mass with ultrasound-guide. Despite antibiotic therapy, her fever continued. She had a comprehensive work-up for FUO, including rheumatologic, infectious, and malignant etiologies. Magnetic resonance imaging (MRI) scans of the pelvis showed two well defined ovarian lesions, which were suggestive of an ovarian fibroma. MRI findings that are suggestive of gynecological infectious diseases were not detected. Then laparoscopy was scheduled. The patient responded well to surgery and the fever resolved after surgery. She is now in the ninth postoperative month and still has no fever.

Keywords: Ovarian fibromas, Fever of unknown origin, Magnetic resonance imaging

Gynecol Obstet Reprod Med 2015;21:49-51

Introduction

Ovarian fibromas, which belong to the group of sex cord stromal cell tumors, are the most common benign solid tumors of the ovary (representing four percent of all ovarian neoplasms). They are usually unilateral and can occur in women of all ages, with a peak at the perimenopausal age.¹ Clinically, they are asymptomatic, and preoperative diagnosis is often difficult. Because of their solid nature in ultrasonography, they are usually misdiagnosed as leiomyomas. They may sometimes be accompanied by ascites. These tumors are curable by surgical excision.

Fever of unknown origin (FUO) is defined as recurrent fever of 38.3°C or higher, lasting more than three weeks, and which remains unidentified despite at least three days of assessment in the hospital. Diseases underlying FUO are numerous and complicated. We report a case of ovarian fibroma with FUO as a new etiological factor.

¹ Turgut Ozal University Medical School Department of Obstetrics and Gynecology, ² Department of Radiology, ³Department of Pathology, Ankara

Address of Correspondence: İkbal Kaygusuz
Department of Obstetrics and
Gynecology Turgut Ozal University
School of Medicine, Emek
Ankara, Turkey
ikbal_cekmen@yahoo.com

Submitted for Publication: 21. 11. 2013

Accepted for Publication: 09. 04. 2014

Case Report

A 26-year-old woman who was married three months ago was referred to our hospital from a private institution with a complaint of a month-long history of intermittent fever without any other signs or symptoms. She had no significant medical history and was not taking any chronic medications. Physical examination was normal, including body temperature. She had a comprehensive work-up for FUO. The abnormal laboratory test results during the work-up were elevated white blood cell (WBC) count at $11.4 \times 10^9/L$ (normal, 3.6 to $9.6 \times 10^9/L$) and C-reactive protein (CRP) at 36.50 mg/L (normal range is below 5 mg/L). Sonographic imaging study of the pelvis revealed a 35x20 mm hypoechoic appearance in the right adnexal area (suspected as pyosalpinx or hematosalpinx). There was no free fluid in the pouch of Douglas. Based on this finding, the patient was referred to a gynecologist. She had regular menstrual cycles and her last period had been eighteen days prior to admission. She had no history of sexually transmitted infections. On pelvic examination, the vagina and cervix were observed to be normal, but there was tenderness in the right adnexal area. Tumour markers, including cancer antigen (CA) 125, CA 15-3, CA 19-9, carcinoembryonic antigen (CEA), alpha-fetoprotein (AFP) and beta-human chorionic gonadotropin (β HCG), were normal.

She was admitted to the gynecology service with a diagnosis of pyosalpinx. Metronidazole and ceftriaxone antibiotics were administered. Pus drainage was then planned but 3cc of serous material was drained from the adnexal mass with ultra-

sound-guide, but there were no leukocytes or bacteria in the microscopic examination. Moreover, its culture was negative. With interventional radiologists recommendation computed tomography (CT) was performed to patient. CT (Brilliance 64 Philips Medical Systems) with intravenous contrast material revealed a 56x25 mm hypodense lesion with subtle contrast enhancement in the right adnexal region and, anterior to it, 20x20 mm of component that was enhanced moderately. The left ovary and uterus were normal, with no ascites or lymphadenopathy. The other finding in the CT scan was thickening of the head of the pancreas, but the other abdominal organs were normal. She was referred to a gastroenterologist because of the thickening of the head of the pancreas and ongoing fever. After 48 hours, the patient's general condition was good and had stable vital signs, CRP levels decreased to 12.17 mg/L, WBC level decreased to $10.7 \times 10^9/L$. The patient was discharged with oral antibiotics for 14 days treatment. After fever-free one week, the patients fever started again and this time triple antibiotic treatment (Rocephin + ciprocid + biteral) was started. On the tenth treatment day the patient had still fever and she referred to the infection doctor, who changed the antibiotics with avelox and scheduled to perform magnetic resonance imaging (MRI). It was performed using a 1.5-T MR system (Achieva; Philips Medical Systems) with a standard body coil. MRI scans of the abdomen revealed normal parenchymal appearance in the head of the pancreas, and gastroenterology accordingly planned a follow-up. Moreover, the patient had completed a comprehensive work up for FUO, including analyses of urine culture, blood culture, chest radiography and rheumatologic, infectious, and malignant etiologies. MRI scans of the pelvis showed two well-defined ovarian lesions (anterior 18x18 mm, post 34x25 mm) that were suggestive of an ovarian fibromas (Figure 1). Lesions were isointense compared with the uterine myometrium on T1-weighted and hypointense T2-weighted images. Subtle enhancement was observed on postcontrast T1-weighted sequences. Although the clinical presentation of the patient may suggest acute infectious gynecologic diseases, pelvic abscess was not considered since there was no fluid-filled, contrast enhancing thick-walls, and gas bubbles within the mass. The patient was scheduled for laparoscopy. In laparoscopic exploration the uterus, left tube, and left ovary looked normal. Right ovary had a fibrotic mass which covered it totally. There was no finding of ovarian torsion or abscess in the right ovary. Cecum was adjacent to right side of the pelvic wall and the appendix was dilated, but intestinal obstruction or abnormal appearance of gallbladder and liver were not observed. Peritoneal washings for cytology were performed, and the right ovary was totally excised successfully and sent to frozen. Intraoperative frozen assessment was benign, peritoneal wash mai was reported to be free of atypical cells mai. Then appendectomy was performed and the operation was concluded. The patient responded well to surgery and the fever resolved afterwards. She was discharged on the second day post-surgery. Macroscopic

and microscopic examination of the mass had no finding of inflammation or abscess, microscopic examination showed an ovarian fibroma, (Figure 2). She is now in the sixth postoperative month and still has no fever.

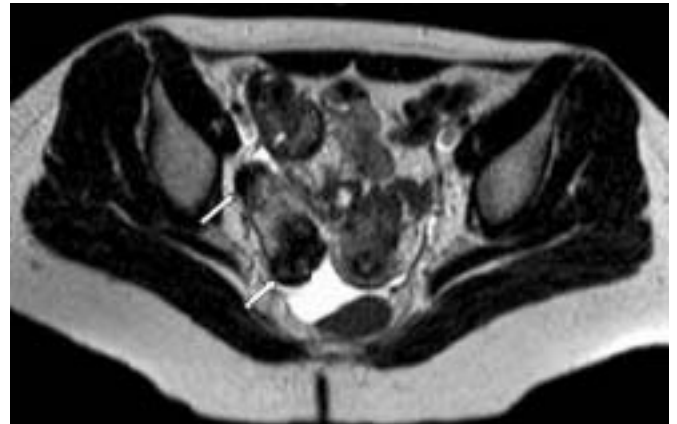

Figure 1: Axial T2-weighted MR image shows two ovarian well defined lesions (arrows; anterior 18x18 mm, posterior 34x25 mm) with very low signal intensity, a finding that is suggestive of an ovarian fibroma

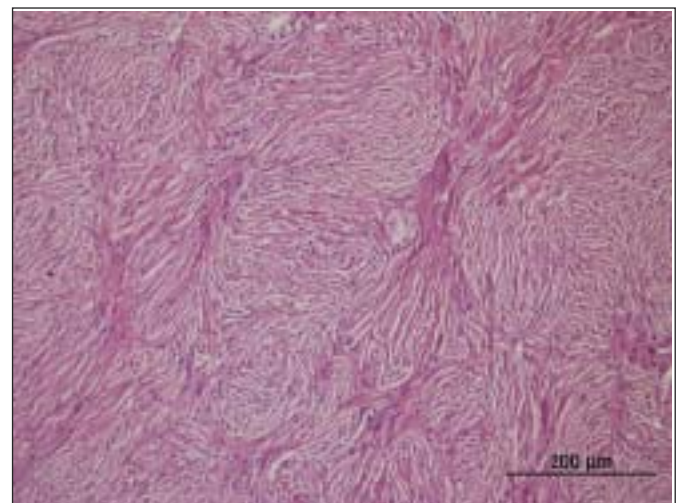


Figure 2: The microscopic appearance of fibroma. The tumor showing, bland nucleus, and a suggestion of a storiform pattern of growth (HEX200).

Discussion

Our patient has received different diagnosis on the basis of imaging findings. Hypoechoic / hypodense appearance that observed on the right adnexal region on sonography and CT examinations was attributed to pyosalpinx in the light of clinical setting. MRI has been diagnostic modality in this case.

FUO was first described by Petersdorf et al. in 1961. Etiological studies have demonstrated that infections, malignancies and rheumatologic diseases are the most common causes. To the best of our knowledge, ovarian fibroma has not previously been reported as a cause of FUO in the literature.

Patients with FOU often have insignificant symptoms and

their physical examination findings are usually atypical. If a patient has typical findings, diagnostic tests are usually successful, but if the findings are atypical, diagnostic work-up for FUO is often unsuccessful, and may lead to additional invasive procedures. Diagnostic CT of the abdomen is one of the initial investigations in assessment of FUO since it has a high diagnostic yield. Unfortunately, in at least one-fifth to one-third of the cases, the diagnosis still cannot be made.² Therefore, laparotomy or laparoscopy is needed in cases in which non-invasive and other invasive diagnostic methods fail to yield a diagnosis.

Diagnosis of ovarian fibromas before surgery is often difficult. They have no characteristic symptoms or sonographic findings. They are usually misdiagnosed preoperatively because of the solid component. In our case, the diagnostic work-up for FUO, which included rheumatologic, infectious, and malignant etiologies, were not able to detect the exact pathology. The main finding of this work-up was an adnexal mass. Laparoscopy was then performed, and the fibroma was safely removed. The patient had no more fever. One of the limitations of our study is that we couldn't add the intraoperative or postoperative photos of our since we did not have a plan to write a case report in the time of surgery. With adding the photos it would be more convincing for the readers.

Adnexal torsion is one of the gynecologic emergencies. If the diagnosis is delayed it may lead to loss of ovary with an effect on future fertility. On rare cases patients with adnexal torsion may have fever because of the peritonitis which is the other consequence of late diagnosis of adnexal torsion.³ In our case there was no finding of adnexal torsion in the right ovary during laparoscopic exploration, therewithal abscess. The patient's clinical findings were consistent with the abscess in the first assessment. But observing serous material drainage from the mass, made us exclude this diagnose. Despite the comprehensive work-up for FUO, infectious etiology (on intra-abdominal or other placement) can not be excluded with certainty. The patient was administered antibiotics before drainage and continued for a long time. During laparoscopy no infectious focus was detected in intra-abdominal site, this may be the result of prolonged use of antibiotics.

It is difficult to explain the cause of the fibroma-related FUO in this case. We couldn't show or prove any certain cause and effect relationship with fever and ovarian fibroma. It is known that ascites is present in more than 50% of ovarian fibromas.¹ Therefore, it would not be surprising to find high cytokine levels in fibroma cases. We speculate that fever might have been as a result of cytokine production; although none of standard textbooks mention this condition. However, further studies are needed to determine the presence of cytokines and whether they are related directly to the ovarian fibroma or to the accompanying ascites.

Another known fact that uterine leiomyomas, the most common solid tumor of the female genital tract, sometimes

undergo degeneration, depending on their location or size. It is reported that degeneration may cause fever.⁴ Our case did not show any finding of degeneration, but when investigating the etiology of fever, degeneration among the masses is an important finding which should be kept in mind.

In brief, fibromas are rare but still the most common benign solid tumors of the ovary. There is no reported case about ovarian fibroma as a possible cause of fever as presented in this case. It would be helpful that this case report be added to the literature and presented to the attention and evaluation of scientists.

Nedeni Bilinmeyen Ateşin Olası Sebebi olarak Overyan Fibrom

ÖZET

Fibromlar overin en sık görülen iyi huylu solid tümördür. Klinik olarak asemptomatiktirler ve ameliyat öncesi tanı genellikle zordur. Bu yazıda nedeni bilinmeyen ateş (NBA) sebebi olarak bir overyan fibrom olgusu sunulmaktadır.

26 yaşındaki kadın hasta 1 aydır aralıklı devam eden ateş nedeniyle hastanemize sevk edildi. Ultrasonografi ve pelvik bilgisayarlı tomografi taramaları sağ adneksiyal alanda bir hipoekoik görünüm gösterdi ve klinik bulguların ışığında hastaya pyosalpinx tanısı konuldu. Püü drenajı planlandı ama ultrasonografi eşliğinde adneksal kitleden 3 cc seröz materyal drene edildi. Antibiyotik tedavisine rağmen hastanın ateşi devam etti. Romatolojik, enfeksiyöz ve malign etyolojiler dahil, NBA için kapsamlı tetkikler yapıldı. Pelvisin manyetik rezonans görüntüleme (MRG) taramaları overyan fibromu düşündürülen iyi tanımlanmış overyan lezyon gösterdi. MRG'da jinekolojik enfeksiyon hastalıkları düşündürülen bulgular tespit edilmedi, Sonra laparoskopi planlandı. Hasta ameliyata iyi yanıt verdi ve ateş ameliyattan sonra düzeldi. Hastamız şimdi ameliyat sonrası dokuzuncu ayda ve hala ateşi yok.

Anahtar Kelimeler: Overyan fibromalar, Nedeni bilinmeyen ateş, Manyetik rezonans görüntüleme

References

1. Son CE, Choi JS, Lee JH, Jeon SW, Hong JH, Bae JW. Laparoscopic surgical management and clinical characteristics of ovarian fibromas. *JSLs* 2011;15(1):16-20.
2. Dai W, Chung KS. Carcinoma of Colon: a rare cause of fever of unknown origin. *Chin J Cancer Res* 2012; 24(2):157-60.
3. Tolga Güler O, Baş KK, Uygur D. The consequences of late diagnosis of adnexal torsion. *Am Surg* 2011;77 (9):E195-6.
4. Han SC, Kim MD, Jung DC, et al. Degeneration of leiomyoma in patients referred for uterine fibroid embolization: incidence, imaging features and clinical characteristics. *Yonsei Med J* 2013;54(1):215-9.